

Mirero Dental Clinic
Dr. Jaemin Lee

Full mouth rehabilitation with digital workflow



Solutions featured:

3Shape TRIOS
3Shape Dental System
3Shape Implant Studio

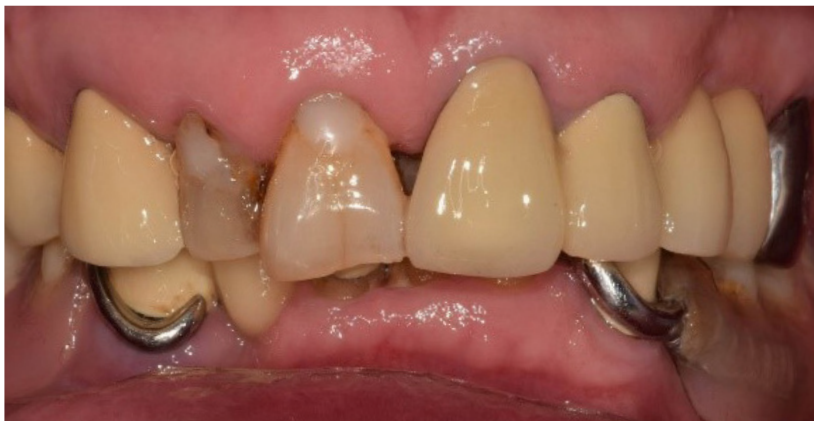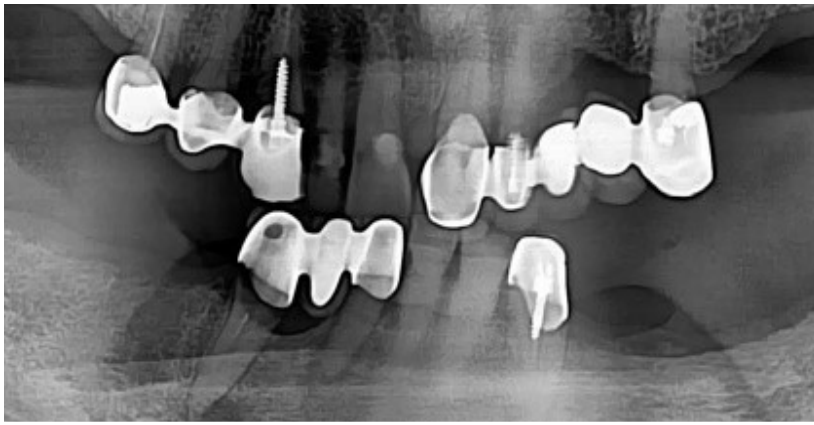


Fig. 1. Panoramic X-ray and patient photo taken on first visit

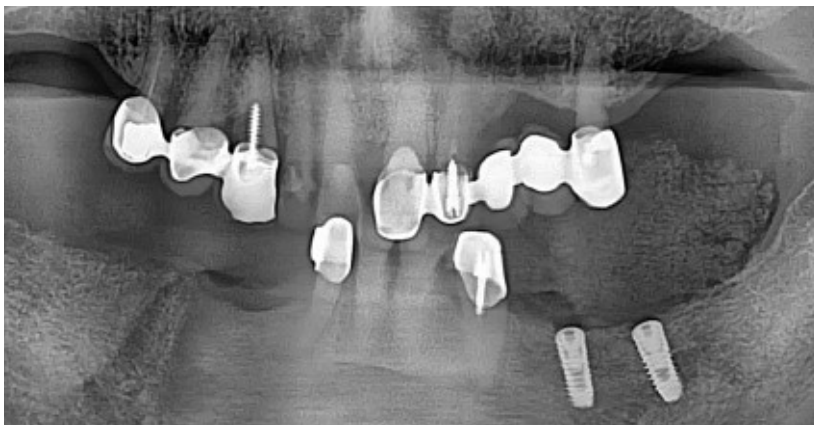

Fig. 2. #43 was extracted on the first treatment day. Implants were placed on #34, #35 position.

Case information

On first visit, the patient was wearing a removable partial denture on lower jaw and was having problems with 3-unit bridged crowns on lower right side. The patient wanted implants for teeth #34-#35 and #43-46. From X-rays, periapical lesions around the root tip of #43 and #41 were seen. There were also secondary caries around the margin of bridged crowns from #41 to #43.

The patient understood that all these teeth needed to be extracted at that time. But the patient did not accept the extraction of #41 for economic reason. The patient wanted to keep his old RPD during the treatment and not remain edentulous. On first visit, the patient was wearing a removable partial denture on lower jaw and was having problems with 3-unit bridged crowns on lower right side. The patient wanted implants for teeth #34-35 and #43-46.

Treatment plan

1st phase

Extraction of #43
 Placing implants on #34, 35
 Repair of RPD to be used as a temporary denture
 Finishing the final prosthesis of 2-unit implant bridge from #34 to #35

2nd phase

Placing implants on #42, #44, #45
 Finishing the final prosthesis of 4-unit implant bridge from #42 to #45

Intended final outcome

2-unit implant bridge from #34 to #35
 4-unit implant bridge from #42 to #45

Treatment description

Treatment Day 1

On the first treatment day, #43 was extracted and two implants were placed on the left side of the lower jaw as planned.

RPD was repaired to be used as a temporary denture.

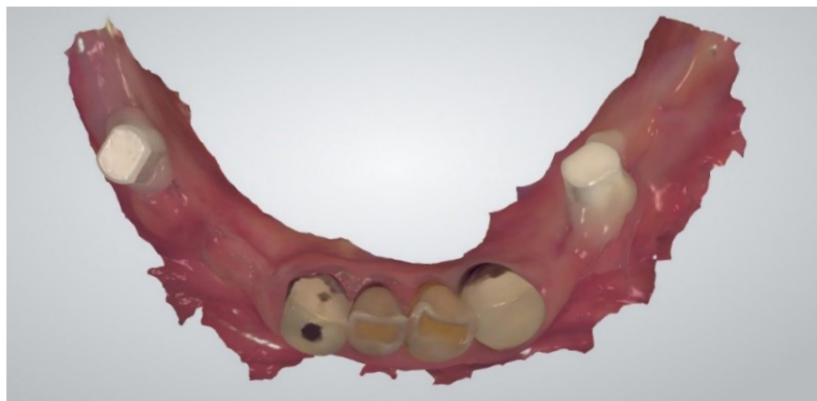

Fig. 3. TRIOS Intraoral Scan Image with Markers on Gingiva

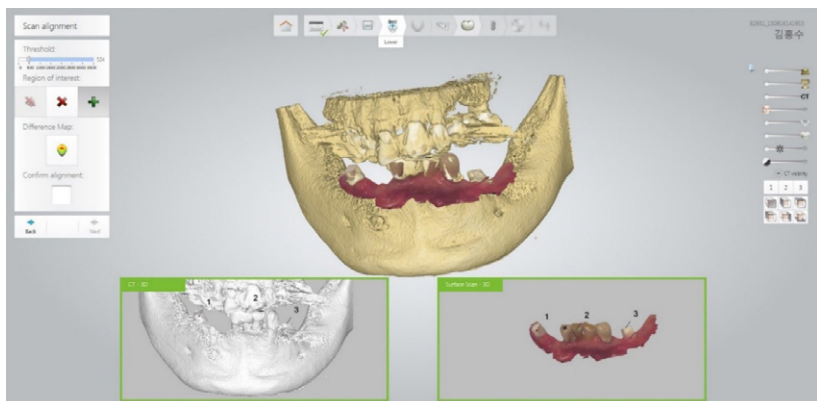


Fig. 4. Scan Alignment

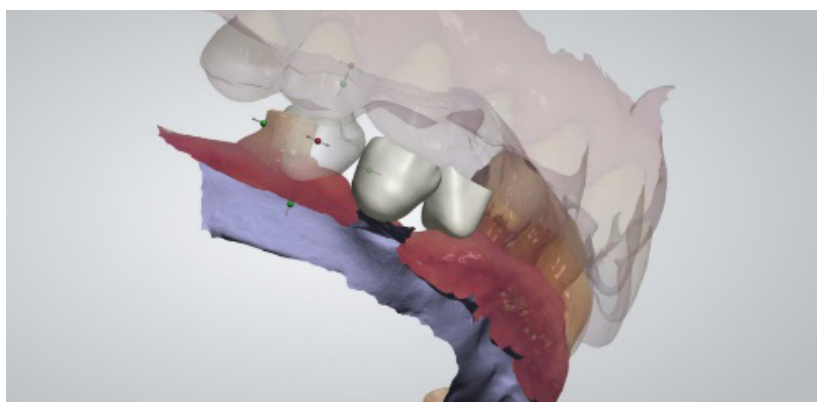


Fig. 5. Provisional Crown Design Figure

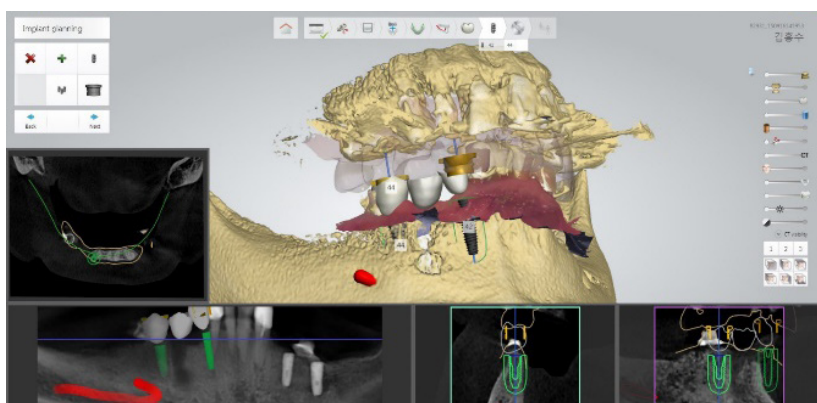


Fig. 6. Implant Planning

Alteration of the plan after 5 weeks from the first treatment

After 5 weeks, the patient's RPD broke and was non-repairable. This meant beginning the treatment on the right side earlier than expected.

As the patient did not want to be edentulous during treatment, I suggested two ways for making a temporary prosthesis. One was to create a new temporary denture, and the second was to immediately load an implant prosthesis. I recommended guided surgery and an immediately loaded implant prosthesis. The patient accepted the guided surgery with the temporary prosthesis. I used Implant Studio to create a surgical guide and perform an immediate loading.

Scan alignment

Aligning the CT image and intraoral scans is a key when using Implant Studio. This is accomplished by choosing three points on the scans. Normally natural teeth are the best choice for the integration, because they are not blurred in CT image and are easily seen in the oral scan image. In this picture, PFM crowns were blurred in CT image and due to the multiple loss of teeth, both end sides of lower jaw did not have points to use as integration points. In this case, the markers that were placed acted like natural teeth to facilitate the integration and make the data integration precise.

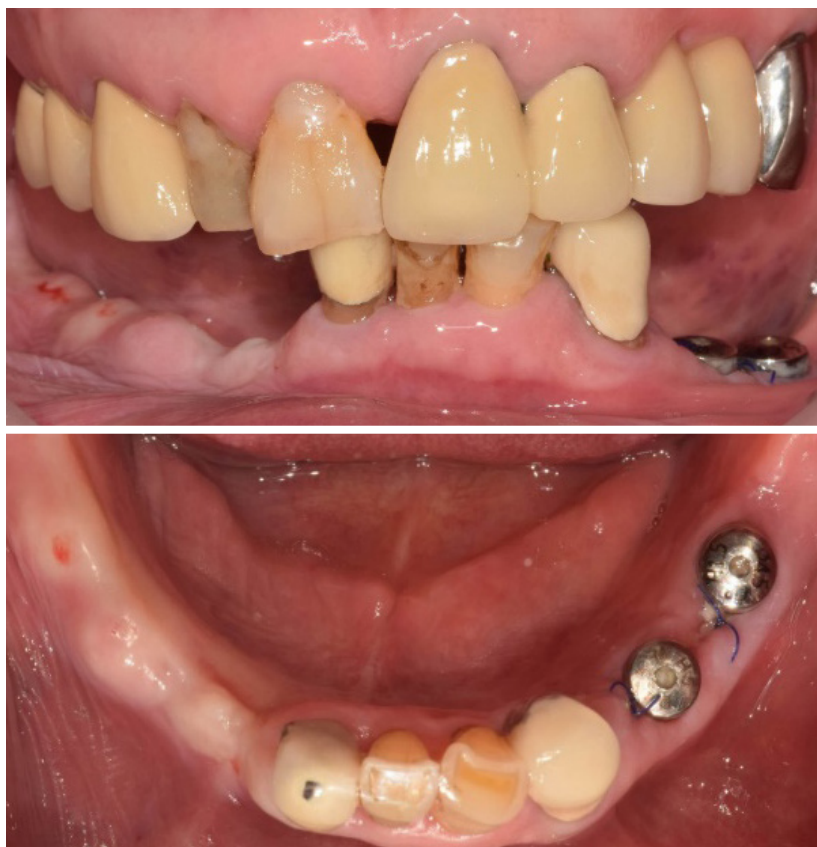

Fig. 7. Photos taken prior to surgery

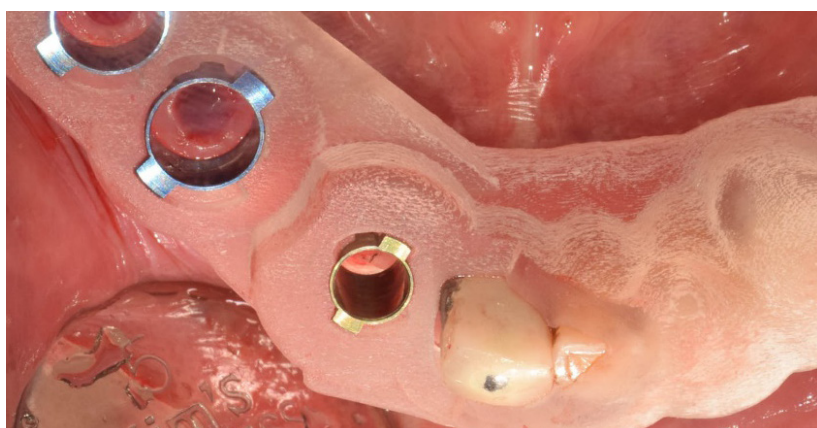


Fig. 8. Placement of the Surgical Guide and Drilling

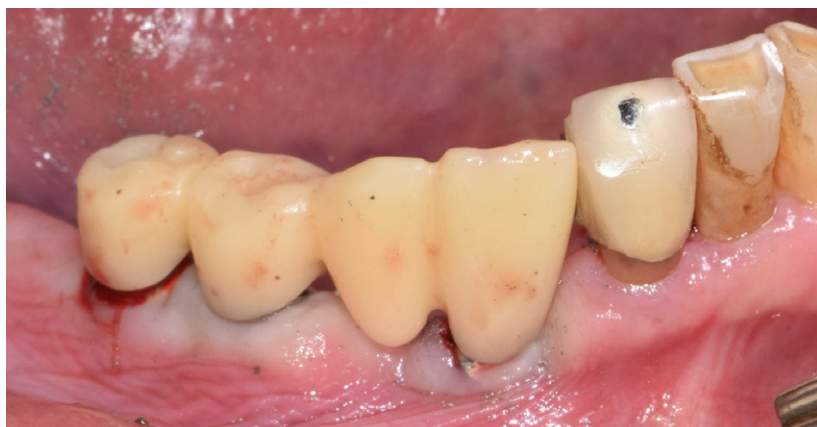

Fig. 9. Provisional Prosthesis seated

Surgical guide fit nicely without any additional fixations into the bone. The guide is made from the accurate soft tissue model taken from the TRIOS intraoral scan data.

Flapless surgery with little tissue damage.

At final seating, the originally placed provisional crowns on both sides were severely worn. Due to the abrasion of crowns, the bite of this patient became unstable.

As a result, I delayed making final crowns, and decided to make provisional prosthesis including customized Ti abutments on the left side first, as the crowns on the right side were preserved better than left. This was intended to re-establish the occlusal relationship to help support the final prosthesis better.

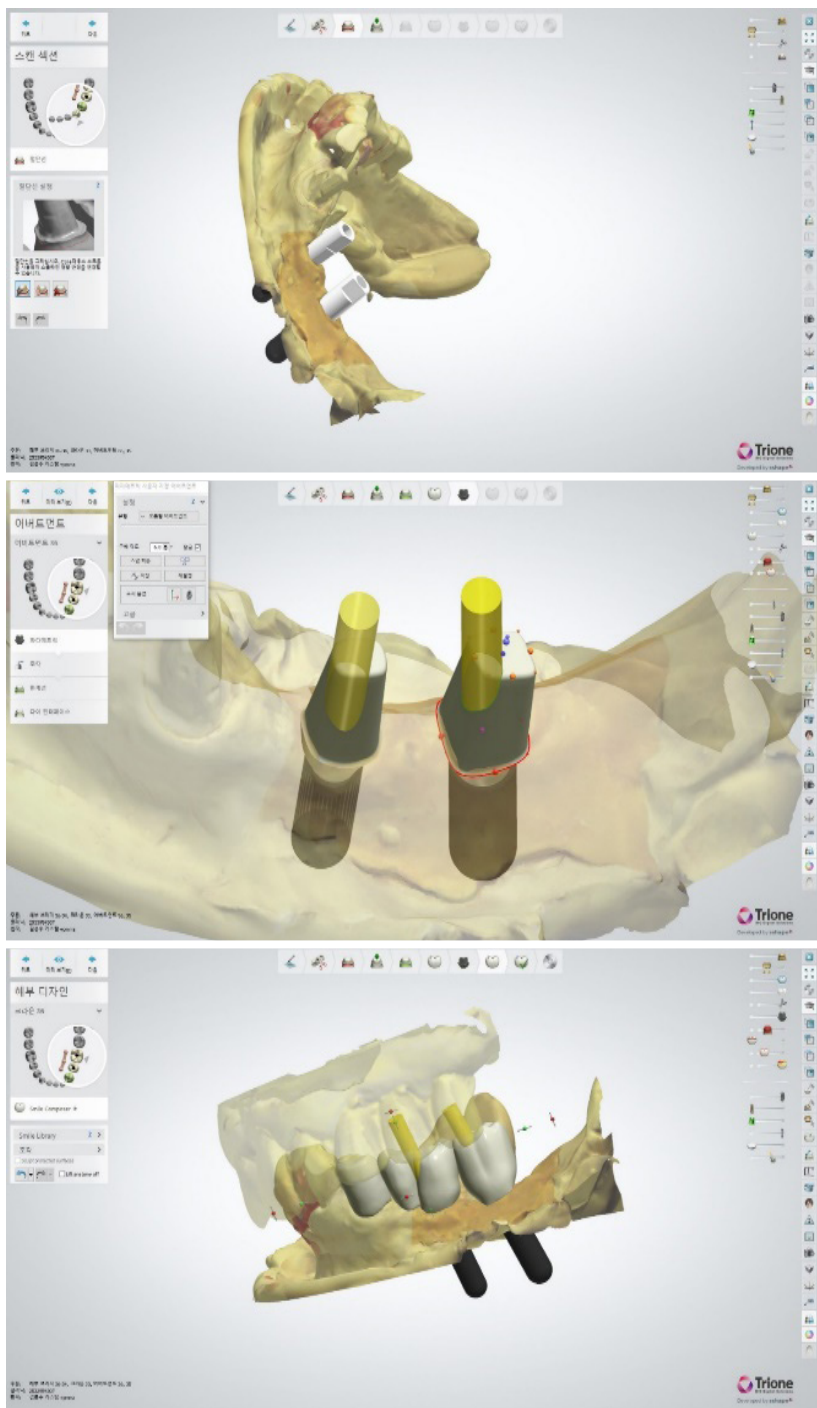


Fig. 10. Designing Ti Customized Abutments and PMMA Provisional Crowns in Dental System using D2000 impression scan

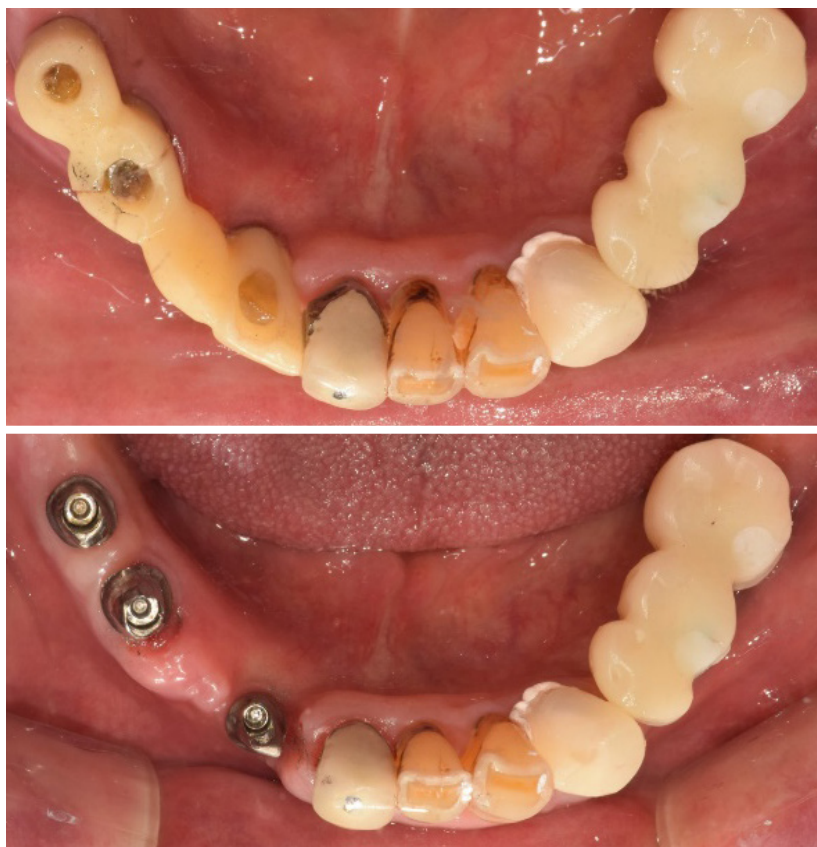

Fig. 11. Seating PMMA Crowns on left side

New PMMA crowns were seated on the left side. After removal of the PMMA crowns on the right side, an impression was taken. As the bite became more certain after seating new crowns on the left side, I decided to make full contour zirconia crowns for final prosthesis with the impression taken then. As seen in the bottom picture, figure 11, the soft tissue around the abutments was secured nicely through the immediate loading period.

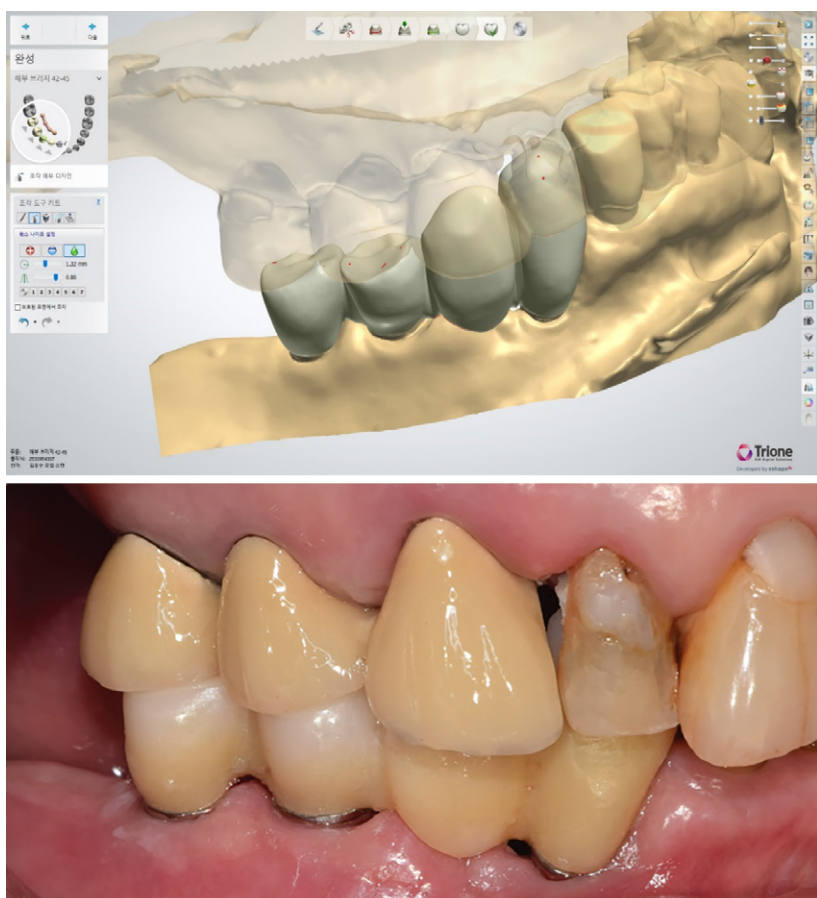
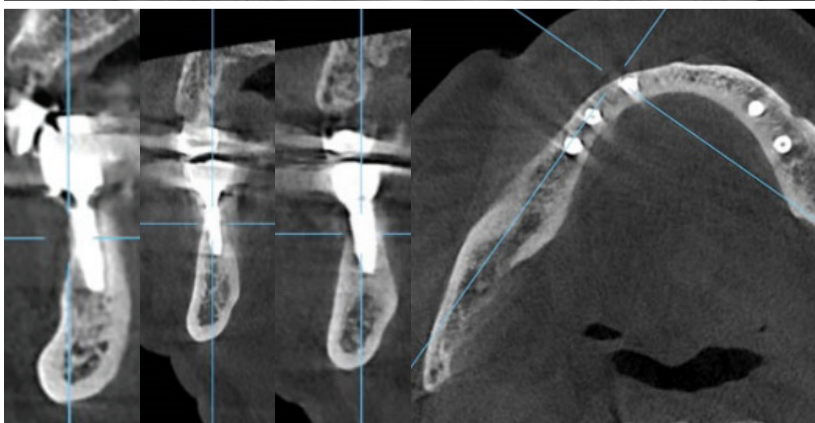
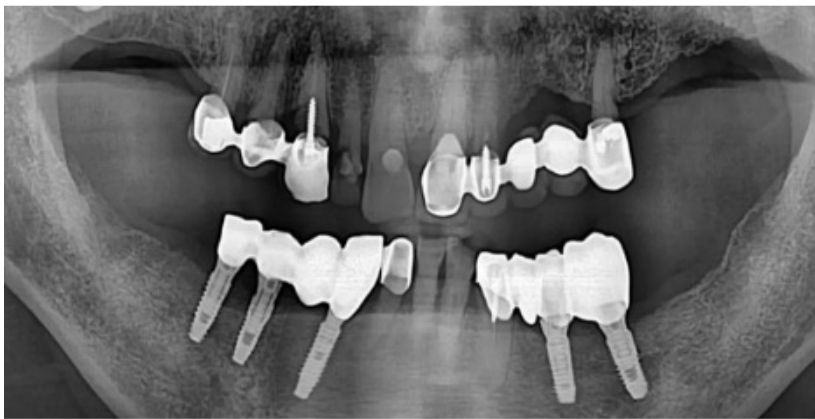
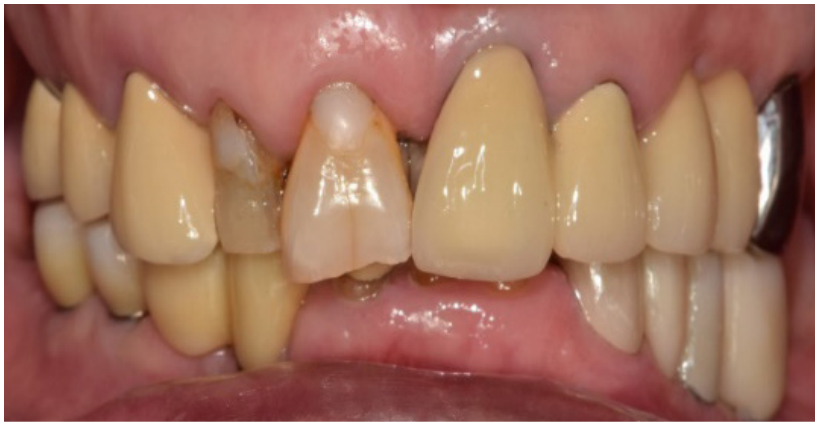
Fig. 12. Full Contour Zirconia Crowns on the Right Side designed and seated

Final crowns seated nicely. Customized Ti abutments for temporary crowns were used for the final prosthesis again.



CBCT and Panoramic X-ray view show implants placed correctly at exact locations. Even after the 2 months of immediate loading period, marginal bone loss not seen.

Fig. 13. Photos, CBCT, Panoramic X-ray View of Post Treatment

About Dr. Jaemin Lee

Dr. Jae-min Lee opened the Mirero Dental Clinic in 2010. Since beginning his journey with digital dentistry in 2015, he has focused on optimizing the digital workflow. He currently uses 3Shape TRIOS® for intraoral scanning as well as the 3Shape D2000 lab scanner for model scanning at his laboratory. Lee designs and produces restorations using 3Shape CAD/CAM software, Dental System, Implant Studio, and OrthoAnalyzer for his practice. At present, he also works with 3Shape to further develop integrated chairside workflows.

Implant Studio benefits according to Dr. Lee

1. Real prosthetic driven surgery, assuring exact placement and path of implants for final prosthesis
2. Save time by placing provisional prosthesis along with the placement of implants
3. Avoid the damage of important anatomic features, like Inferior Alveolar Nerve, Sinus Cavity
4. Minimally invasive surgery with flapless reflection

Dr. Lee talks about Implant Studio

"Implant Studio enables me to intuitively plan a surgery based on the prosthetic considerations. As this case illustrates, being able to virtually place and verify the implant position for the final prosthesis prior to surgery is extremely valuable.

The ability to fabricate and immediately load a provisional prosthesis because I have a practice lab solution is also very beneficial to my patients. As illustrated in this case, I was able to quickly provide a provisional for my patient even when it was not originally planned for.

For restorative design, I use Dental Designer in combination with Implant Studio. The consistent data sets between the two software enable me to work confidently. Consistent data also means that I am able to send my designs to dental labs when relevant, for larger cases, and know that the data will not be distorted.

Being able to design and manufacture a provisional at my practice is also an enormous benefit for my fully or partially edentulous patients who are unable to eat without having a temporary prosthesis. Because of CAD/CAM, they are able to leave my office with a prosthesis.

Besides the prosthetic advantage, Implant Studio also enables me to create a planned surgical strategy. For example, using drill protocols created in Implant Studio, I can avoid damaging important anatomical features like, the sinus cavity, nasal cavity and inferior alveolar nerve during surgery.

There are many dentists who believe that they do not need guides for their surgeries. Of course, this is true. However, I believe that if a skilled oral surgeon uses Implant Studio, he or she will improve the quality of treatment in both the surgical and prosthetic respect.

For dentists unfamiliar with implant surgery, Implant Studio can serve as your guide to performing implant procedures. It takes you step-by-step through the procedure.

Additionally, with Implant Studio, the entire surgery can be finished without flap reflection. This means patients incur less damage during surgery and from what I have experienced, patients truly appreciate this, because there is less pain and discomfort post-surgery."

About 3Shape

3Shape is changing dentistry together with dental professionals across the world by developing innovations that provide superior dental care for patients. Our portfolio of 3D scanners and CAD/CAM software solutions for the dental industry includes the multiple award-winning 3Shape TRIOS intraoral scanner, the 3Shape X1® CBCT scanner, as well as market-leading scanning and design software solutions for both dental practices and labs.

Two graduate students founded 3Shape in Denmark's capital in the year 2000. Today, 3Shape employees serve customers in over 100 countries from 3Shape offices around the world. 3Shape's products and innovations continue to challenge traditional methods, enabling dental professionals to treat more patients more effectively.

Let's change dentistry together

www.3shape.com

3shape 